Investigations, ID 75

Patterns of cortical grey matter thickness reduction in multiple sclerosis

Fujimori J [1], Fujihara K [2, 3], Wattjes MP [4], Nakashima I [1]

1 Division of Neurology, Tohoku Medical and Pharmaceutical University, Sendai, Japan
2 Department of Multiple Sclerosis Therapeutics, Tohoku University Graduate School of Medicine, Sendai, Japan
3 Department of MS Therapeutics, Fukushima Medical University School of Medicine and MS and NMO Center, Southern Tohoku Research Institute for Neuroscience, Koriyama, Japan
4 Department of Diagnostic and Interventional Neuroradiology, Hannover Medical School, Hannover, Germany

Abstract

Objective: To examine the patterns of cortical grey matter thickness in multiple sclerosis (MS) patients.

Methods: Seventy-four MS patients and 21 healthy controls (HCs) underwent high-resolution T1-weighted volumetric MRI examinations to measure brain cortical thickness in a total of 68 regions of interest. Using hierarchical cluster analysis with multivariate cortical thickness data, cortical thickness reduction patterns (CPs) were cross-sectionally investigated in MS patients.

Results: The MS patients were categorized into three CP groups. Most of the regional cortical thickness values were equivalent between the HC group and the CP1 group but were moderately and severely decreased in the CP2 and CP3 groups, respectively. Only the thicknesses of the temporal lobe cortices (superior, middle, and inferior temporal cortex and fusiform) and the rostral middle frontal cortex were significantly different among the CP1, CP2, and CP3 groups. In contrast, temporal pole thickness reduction was evident exclusively in the CP3 group, which was also characterized by increased lesion loads in the temporal pole and the adjacent juxtacortical white matter, dilatation of the inferior horn of the lateral ventricle, severe whole-brain volume reduction and longer disease duration. Although cortical atrophy was significantly more common in the progressive phase, approximately half of the MS patients with the severe cortical atrophy pattern had relapsing-remitting disease.

Conclusion: Our cluster analysis highlighted the progressive nature of temporal lobe cortical atrophy in MS, which may start in the relapsing-remitting phase. Among the temporal lobe cortices, the neurodegenerative change may accelerate in the temporal pole in the progressive phase.

Introduction

A recent cross-sectional study suggested that cortical grey matter atrophy in MS occurs mainly in a nonrandom manner. (Steenwijk MD, et al. Brain. 2016)

Thus, the aim of our study was to investigate nonrandom patterns of cortical thickness reduction in Japanese MS patients.

Methods

Seventy-four MS patients and 21 healthy controls (HCs) were recruited cross-sectionally.

All study subjects underwent high-resolution T1-weighted volumetric MRI examinations to measure brain cortical thickness in a total of 68 regions of interest.

Using hierarchical cluster analysis with multivariate cortical thickness data, cortical thickness reduction patterns (CPs) were cross-sectionally investigated in MS patients.

Results

1. Clinical profiles

Clinical profiles	MS (n=74)	HC (n=21)	MS vs HC
Sex (F:M)	55:19	11:10	NS [a]
CIS / RRMS / SPMS / PPMS	4% / 79% / 16% / 1%		
Age, mean (SD)	40.3 (9.9)	36.2 (13.6)	NS [b]
Duration (years), mean (SD)	9.6 (7.3)		
EDSS score, median	2 (1-3.5)		
Interferon beta / Fingolimod / Dimethyl fumarate / Glatiramer acetate / Natalizumab / Ofatumumab	14% / 51% / 15% / 3% / 3% / 1%		
Brain segmentation vol, mean (SD)	1038836 (111310)	1127191 (121547)	P=0.005 [b]
Cortical white matter vol, mean (SD)	420143 (59029)	466172 (64649)	P=0.004 [b]
Total grey matter vol, mean (SD)	563525 (60249)	613065 (61480)	P=0.003 [b]

[a], p value evaluated by Pearson's chi-squared test. [b], p value evaluated by the Wilcoxon test.

2. Cluster analysis identified three cortical thickness reduction patterns (CPs) based on cortical thickness data

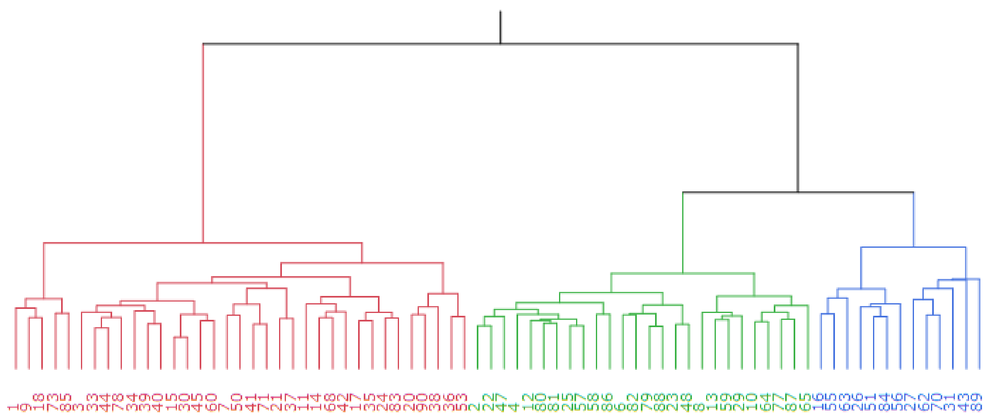

3. A parallel plot of the cluster means showed that there were clear differences among all of the cortical thickness reduction patterns

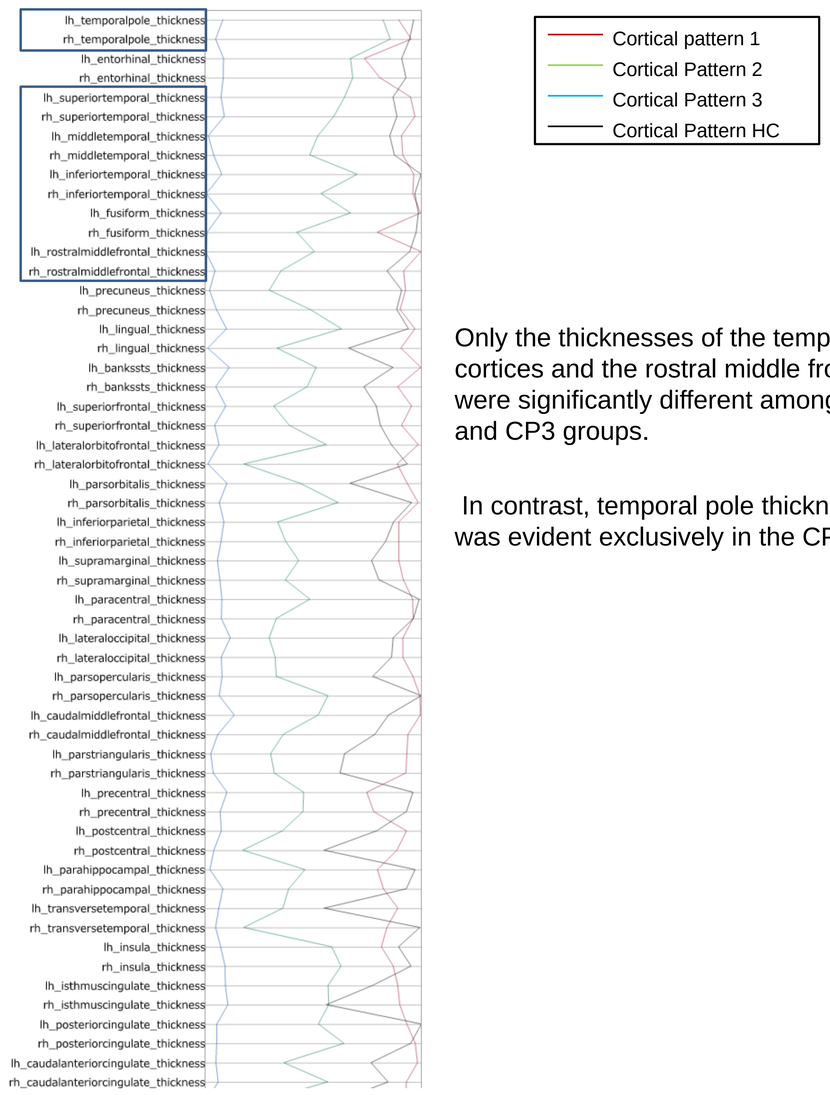

Only the thicknesses of the temporal lobe cortices and the rostral middle frontal cortex were significantly different among the CP1, CP2, and CP3 groups.

In contrast, temporal pole thickness reduction was evident exclusively in the CP3 group.

4. CP3 group was characterized by increased lesion loads in the temporal pole and the adjacent juxtacortical white matter

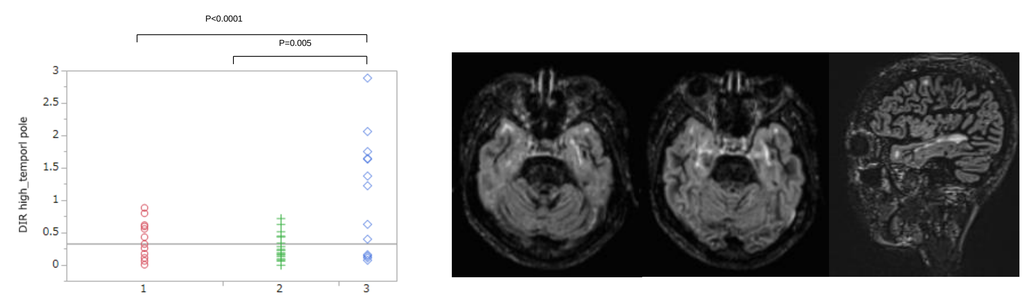

5. Although cortical atrophy was significantly more common in the progressive phase, approximately half of the MS patients with the severe cortical atrophy pattern (CP3) had relapsing-remitting disease.

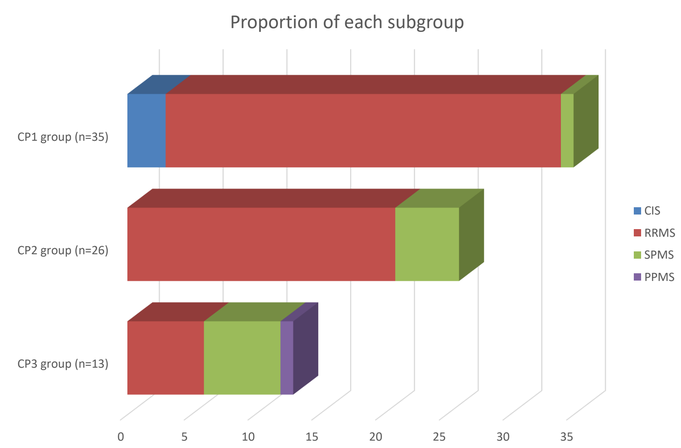

The difference in the proportions of subtypes among CP groups (p=0.0015)

Conclusions

- MS patients can be classified into three cortical thickness reduction patterns (CPs).
- CPs reflect the degree of global cortical atrophy with some uneven distribution.
- The most significant difference among CPs is the degree of temporal cortical atrophy.
- Only when temporal cortical atrophy becomes severe is temporal pole atrophy observed.
- Temporal pole atrophy is associated with demyelinating plaques in adjacent areas.
- Temporal lobe cortical atrophy in MS may start in the relapsing-remitting phase.